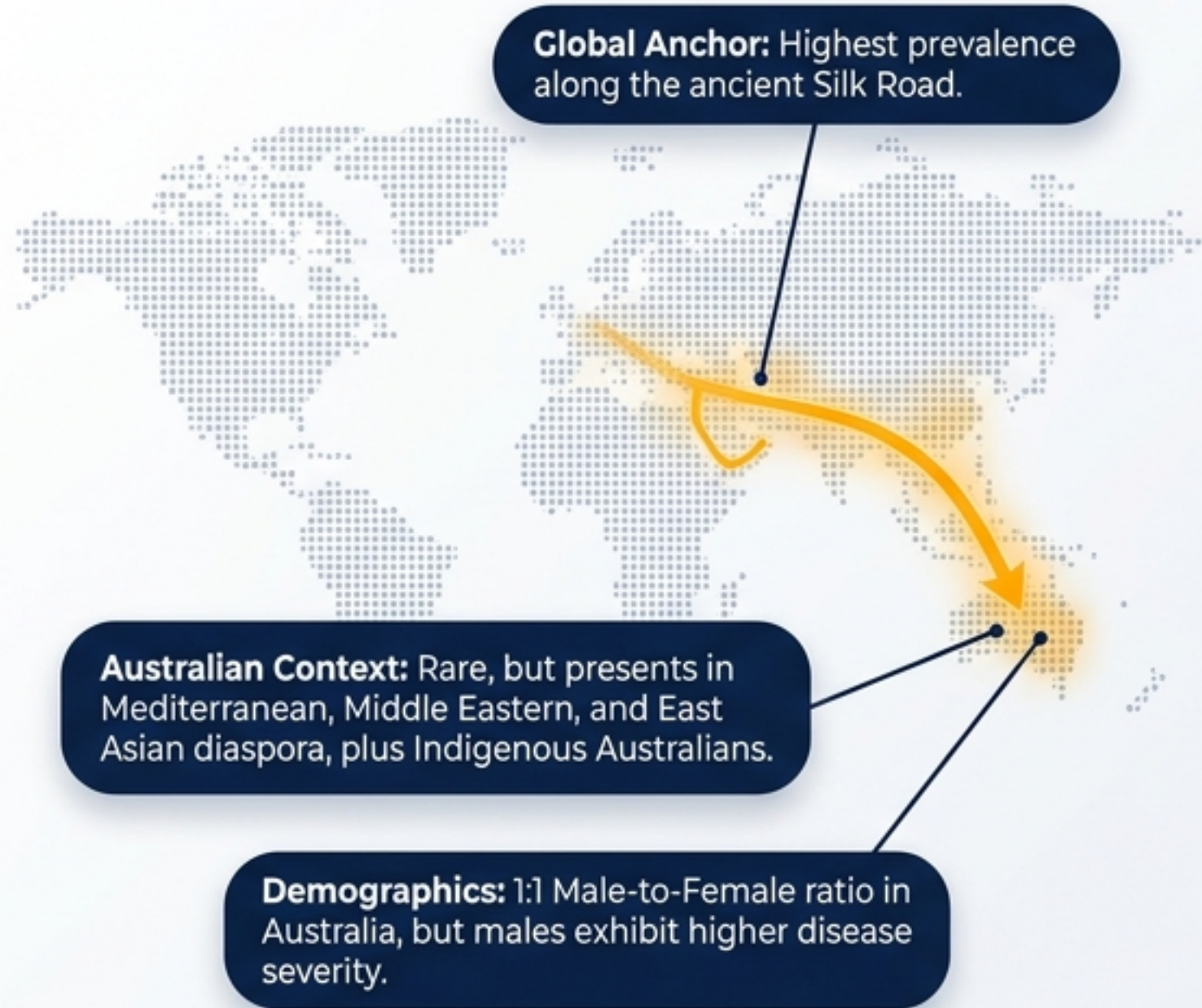


From Surface to Systemic: Decoding Behçet's Syndrome

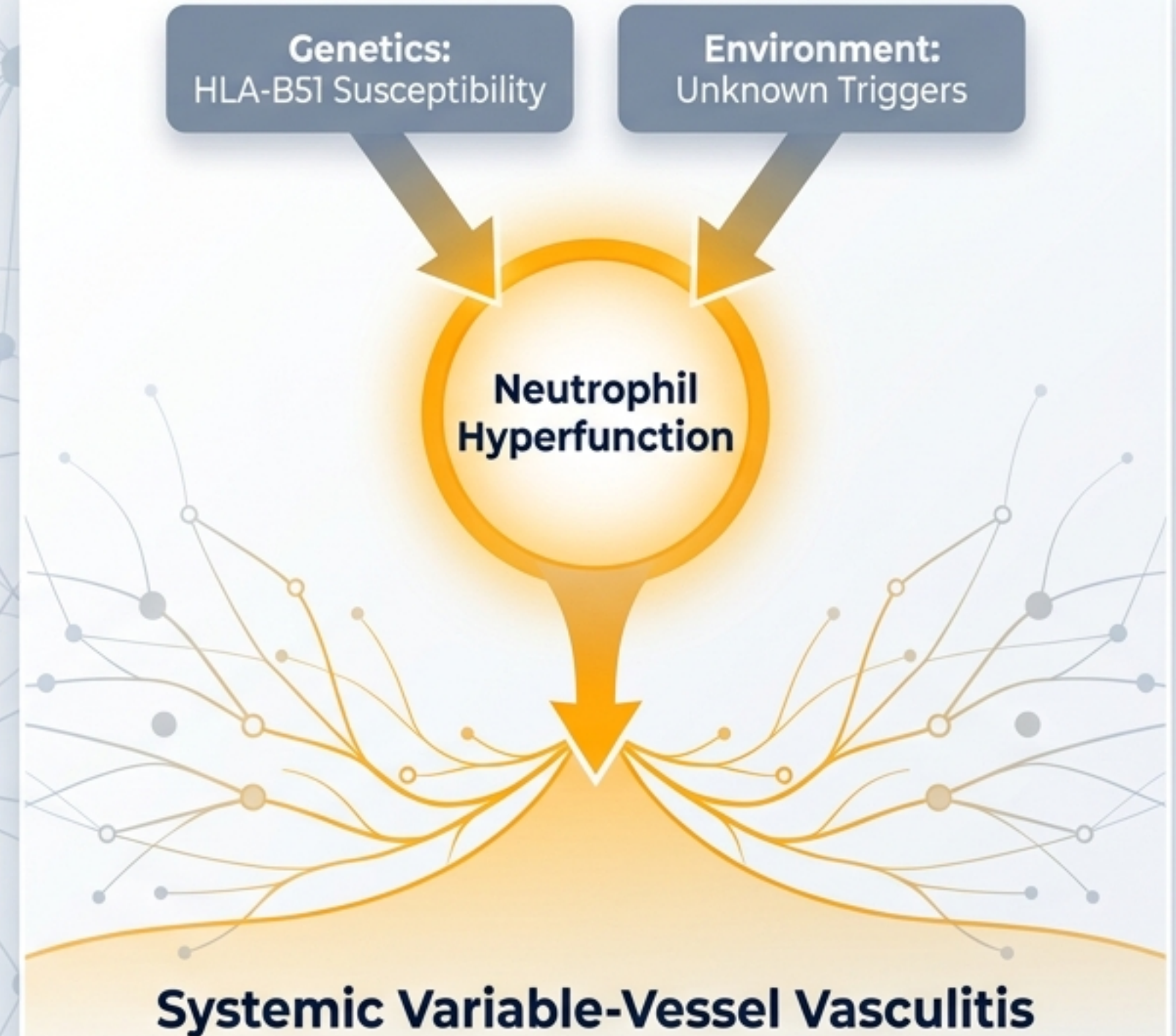
A Clinical Triage and Management Dashboard
for Variable-Vessel Vasculitis

Med2Date Clinical Reference • Visual Architecture by Expert Design

EPIDEMIOLOGY & DEMOGRAPHICS



THE PATHOGENESIS ENGINE



DIAGNOSTIC EQUATION: BEHÇET'S SYNDROME

Mandatory for diagnosis

**Recurrent
Oral Ulcers**

≥3 times per year

+ 2 OF 4

**Recurrent
Genital Ulcers**

Ocular Lesions

Skin Lesions

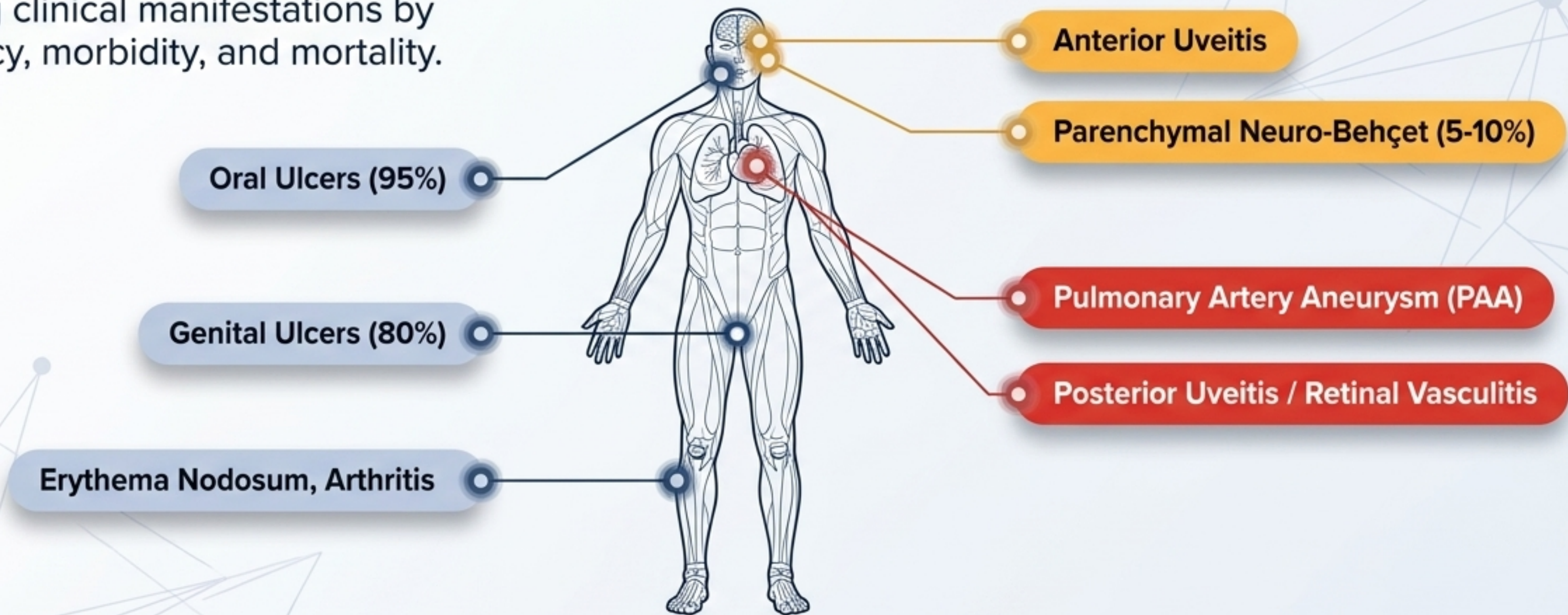
Positive Pathergy Test



Diagnosis is purely clinical. No single pathognomonic laboratory test exists.

BEHÇET'S HEATMAP: SYSTEMIC INVOLVEMENT & RISK

Mapping clinical manifestations by frequency, morbidity, and mortality.

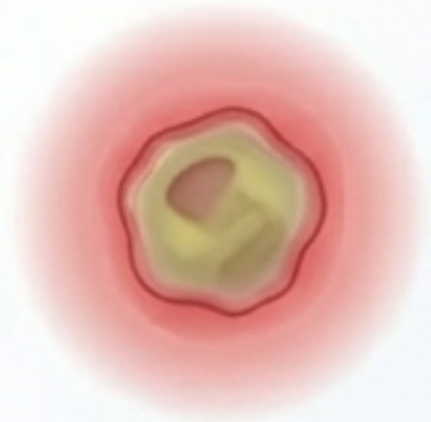

THE CLINICAL CHALLENGE

Triage requires looking past the highly visible, painful surface manifestations (95% frequency) to hunt for silent, sight- and life-threatening systemic involvement.

Recurrent Oral Ulcers: The Mucosal Anchor ($\approx 95\%$ Prevalence)

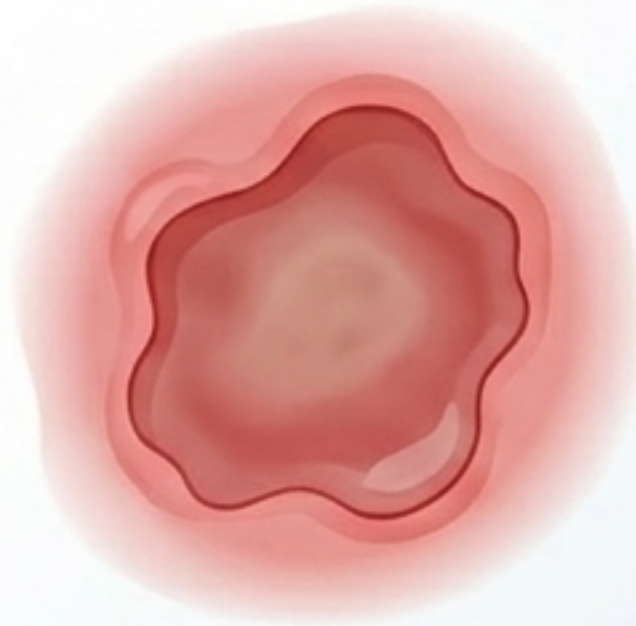
Minor Ulcers



Features: <10 mm, round/oval. Yellow-grey necrotic base, erythematous halo.

Context: Most common presentation.

Major Ulcers

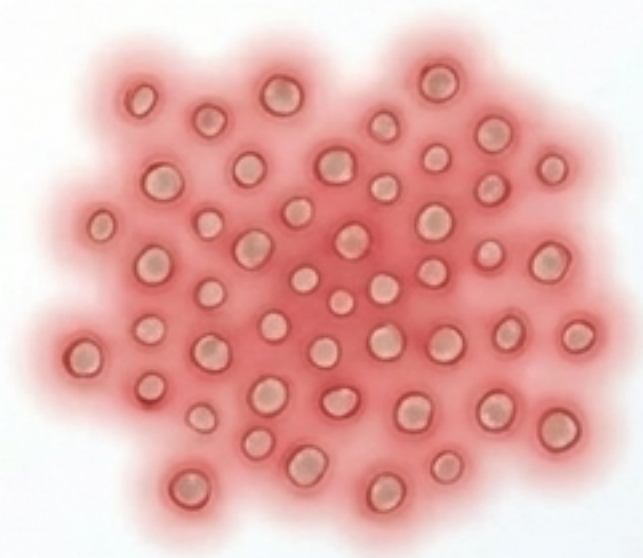


Features: >10 mm, deep, high risk of scarring.




High correlation with severe systemic involvement.

Herpetiform



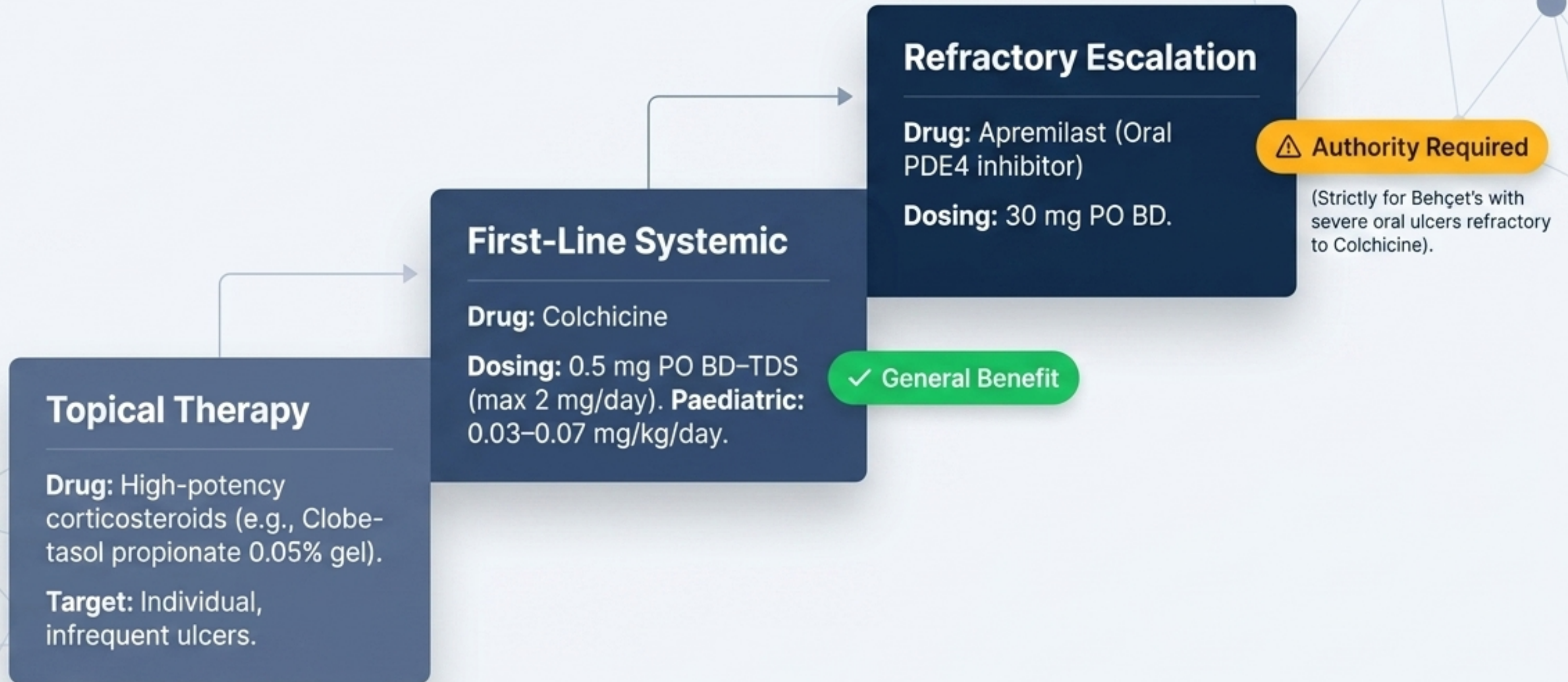
Features: Clustered, pinpoint small ulcers.



Often warrants aggressive systemic therapy.


Behçet's Therapy Staircase: Escalating Management for Oral Ulcers

Progressive treatment strategy based on severity and response.



Mucocutaneous Manifestations: Comparative Analysis of Oral and Genital Ulcers

	Oral Ulcers	Genital Ulcers
Prevalence	≈95% (Often first symptom)	≈80%
Morphology	Minor, Major, Herpetiform	Larger, deeper, often solitary
Primary Locations	Oral mucosa	Males: Scrotum/Shaft. Females: Vulva/Vagina.
Scarring Risk	Low (except Major)	High (Major cause of morbidity)
Management Path	Topical Steroids → Colchicine → Apremilast	Topical Steroids / Sucralfate → Colchicine → Azathioprine/Dapsone

 **Note:** Surgical consult is required for severe genital scarring.

⚠️ Ocular Involvement: The Sight-Threatening Emergency (30–70% of patients)

Ocular Emergency Escalator

Anterior Uveitis

Pain, redness, photophobia.

Posterior Uveitis & Retinal Vasculitis

Floaters, blurred vision.

Retinal ischaemia → Neovascularisation → Vitreous haemorrhage

Irreversible Blindness

Action Protocol Box

Immediate Action: Same-day ophthalmology assessment for ANY visual symptoms.

Acute Flare Suppression: IV Methylprednisolone (1g/day x 3 days) → Oral taper.

Biologic Rescue: Infliximab (5 mg/kg IV) or Adalimumab (40 mg SC).

⚠️ PBS Authority

Vascular Manifestations

Venous (More Common)

DVT, Superficial thrombophlebitis.

Arterial (Rare, Lethal)

Pulmonary Artery Aneurysm (PAA). High mortality from rupture/haemoptysis. Requires CTPA.

The Paradox: Inflammation drives thrombosis.



Immunosuppression

Anticoagulation

Do not attribute vascular events solely to a prothrombotic state. Corticosteroids + Immunosuppression (Cyclophosphamide/TNF inhibitors) are the cornerstone of survival. Anticoagulation remains controversial and carries catastrophic risk if concurrent PAA ruptures.

Neuro-Behçet affects 5–10% of patients and is a primary driver of poor prognosis.

Parenchymal (Most Common)



Target: Brainstem, basal ganglia, thalamus, meninges.

Clinical Picture: Hemiparesis, cranial nerve palsies, psychiatric symptoms.

Imaging: MRI Brain shows T2/FLAIR hyperintensities.

Acute Treatment: IV Methylprednisolone (1 g/day x 3–5 days).

Non-Parenchymal



Target: Venous system.

Clinical Picture: Cerebral Venous Thrombosis (CVT), intracranial hypertension.


Imaging: MR Venography essential.

Acute Treatment: Anticoagulation + Corticosteroids.

Treatment Stratification

Inpatient
Multidisciplinary

Severe / Inpatient MDT

Targets: Posterior uveitis, PAA, Parenchymal Neuro-Behçet, GI perforation. 

Arsenal: High-dose IV Corticosteroids, Cyclophosphamide, Infliximab, Adalimumab.

Mild-Moderate / Outpatient

Targets: Oral/genital ulcers, erythema nodosum, arthritis.

Arsenal: Topical steroids, Colchicine, Apremilast.





Outpatient

Mild-Moderate

Severe / Life-Threatening

Core Principle: No single agent is curative; therapy scales rapidly to suppress inflammation and prevent irreversible organ damage.

The Pharmacotherapy Arsenal Dashboard

Drug Class	Standard Dosing	Key Monitoring/Toxicity	PBS Status
Colchicine	0.5 mg BD-TDS.	Monitor renal function (reduce if eGFR <30, avoid if <15).	 General Benefit.
Apremilast	30 mg BD.	Monitor mood/GI tolerance.	 Authority (Severe Oral Ulcers).
Azathioprine	2–2.5 mg/kg/day.	*Check TPMT/NUDT15 genotype prior. Monitor FBC, LFTs.	 General Benefit.
TNF Inhibitors (Infliximab/Adalimumab)	IFX: 5mg/kg IV (wks 0,2,6, then 6-8 wks). ADA: 40mg SC every 1-2 wks.	Monitor for infection/TB.	 Authority (Refractory/Severe).

Special Populations & Contextual Considerations



Pregnancy Considerations

Safe/Continue:

Colchicine (low risk),
Azathioprine (prevent flares).

Biologics:

Certolizumab pegol preferred
(minimal placental transfer).

⚠️ Contraindicated:

Methotrexate, Mycophenolate,
Cyclophosphamide (Teratogenic).



Renal Impairment & Paediatrics

Renal: Drastic dose reductions required for Colchicine and Cyclophosphamide. Avoid Colchicine with CYP3A4 inhibitors.

Paeds: Often starts mucocutaneous. Treatment is weight-based; TNF inhibitors show good efficacy.



Aboriginal and Torres Strait Islander Health

Clinical Profile: May present with severe mucocutaneous/articular disease. Lower background HLA-B51 prevalence.

Care Delivery: High barrier to MDT specialist access due to remoteness. Utilize telehealth and Aboriginal Health Workers to navigate complex, culturally sensitive symptoms (genital ulcers) alongside high background cardiometabolic comorbidities.